

Mammals Communicate, Infrared Listens Utilizing Infrared Imaging for Injury Identification

*Peter Hopkins, Level II Thermographer, United Infrared, Inc.
Dean R. Bader-DVM, Equine Thermal Imaging Institute*

ABSTRACT

Mammals communicate in a variety of ways. For humans it is in the form of speech. Infants might cry and dogs may yelp or limp to express their pain. When there is a language barrier or no speech at all, how would one communicate pain to a caretaker? Some species, specifically the prey mammals such as the horse, have proven that they mask their pain as a survival technique. This is a perfect example of how Infrared Imaging is an excellent method to be used in the identifying of injuries in many mammals. It is our intent that with this paper we are able to share the many applications we have successfully completed with the use of infrared and in doing so have helped Animal Managers, Zookeepers, Veterinarians and concerned owners to better understand and care for their animals.

INTRODUCTION

At some point in your life you may have either heard about or possibly enjoyed the antics yourself, of a certain character horse that could talk with his owner, sharing his daily thoughts and/or pains. Of course we all know with camera tricks and a treat in hand you could train almost any animal to perform with an end result appearing very realistic. In the real world however, it does not work quite this way, yet humans have discovered and become accustomed to a number of methods of communication. Some common alternatives might be the use of sign language, the written language and the one we all use daily, expressions.

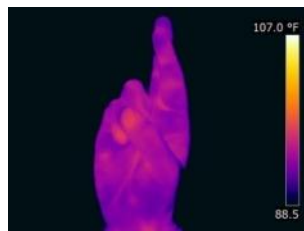


Figure 1. Infrared images sign language for IR


Written Language

Expressions

In this paper, we discuss one of the not-so-common methods of Infrared Imaging, one which helps to facilitate communication thereby reducing the communication learning curve between humans and other species.

PROBLEM

With over 5,000 documented species of mammals and so many unknown or misunderstood forms of communication, we need to find a common ground or method so we can help those suffering in unspoken pain. Think of a baby for instance, we have learned through time that a baby cries commonly when they are hungry, tired or have a wet diaper. We all know there are many other reasons that could exist but it is often a guessing game to identify the exact reason why. Sometimes, it takes a process of elimination in hope of finding the correct diagnosis.



Crying Baby: but why?

Have you ever wondered why certain job titles end with the word “practice”? (i.e. Veterinary Practice, Medical Practice, Legal Practice). Is it possible that because we have this inability of communication that we have to continue to practice to find the real problem? Could Infrared help identify pain in an infant child or animal? Just as physicians have tools such as stethoscopes or magnifying lenses, could not infrared be used as a viable tool?

The medical profession which includes Veterinarians has become more dependent on laboratory tests and data than actual hands on palpation methods of detecting minor changes in the body. Thermal imaging can be the missing link or an additional valuable tool with sensitivity more acute than the human touch. Touch sensitivity is approximately three degrees Fahrenheit whereas thermal imaging has sensitivity in the tenths of a degree Fahrenheit.

Animals like humans vary in response to painful changes in their bodies. Some horses become obviously lame, some may experience minor changes both requiring significant methods of examination to try and detect a cause for the change; whereas other horses will mask their pain and show no visible obvious change in their gait. This is yet another reason why the infrared camera is such a valuable tool when used to evaluate and detect these exact lameness issues. It could take up to two weeks for a lameness problem to manifest itself in order to show obvious signs. Thermal Imaging is the only tool that has shown the visible changes in heat patterns, therefore allowing a Thermal Imaging Tech and a Veterinarian the ability to make immediate changes possibly preventing what could have been a disaster.

THE SCIENCE OF IT

Although X-Rays are very helpful in evaluating bony changes in a horse and reflect some changes such as swelling in the soft tissue, they do not have the capability to evaluate soft tissue changes to the extent of thermal imaging. Thermal imaging shows physiological changes such as increased or decreased circulation, lack of or diminished nerve function as well as swelling. Thermal imaging is also extremely safe allowing the owner to stay with their horse throughout the scan. It is non-invasive relieving the stress from both the owner and the horse of not having to be sequestered behind a lead wall for protection and is notably less expensive in comparison to Radiology, MRI, and Scintigraphy.

The addition of an Infra-Red Camera is very affordable as compared to the addition of most other equipment allowing a Veterinary Practitioner in smaller private practices the ability to expand their services and evaluation techniques.

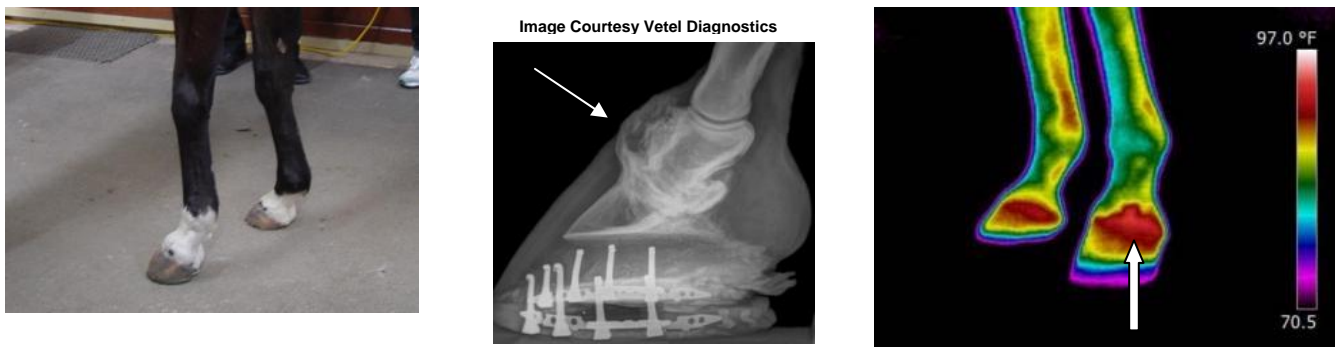


Figure 2. Horse hoof: Visual image

X-Ray Image

Thermal Image

With thermal imaging the differences in symmetry are important compared to the radiograph you see in the above case which shows the problem detected extends above the coronary band. In the event x-rays were done first, the thermal image would add to the understanding of the physiological problems; should the thermal image be done first, then the need for a radiograph becomes helpful. Both images complement each other in the understanding of the problem.

SOLUTION

Infrared is commonly known to be an accepted method for the identification of common electrical problems, moisture leaks and energy loss in buildings, but what about medical applications? As written in an abstract article printed in the International Research Journal titled, "Infrared Physics & Technology" [1], it is explained that through most of the 1970's, infrared medical imaging was viewed as an exciting and promising new technology due in most part to the variety of potential diagnostic applications performed by the US clinical community. The abstract additionally stated that infrared has subsequently disappeared from US medical practice for a number of reasons which include inflated expectations, technical immaturity as well as a substantial amount of misinformation.

Many of the specialists agree that the success of this technology is contingent upon a common ground being put in place primarily covering the protocols and procedures for same. This technology has absolutely matured since the 1970's and is actually at a point where infrared thermography is about to reinvent itself in the medical market place. Not only has the advancement of these cameras grown, they have also increased tremendously in their thermal sensitivity, and now are being sold at an affordable price point. Although our primary medical use has been in the application of veterinary infrared imaging, we choose to believe there are a number of benefits it will provide to the future of human medicine. Infrared is beginning to show a strong acceptance among the medical industry in the field of Breast Thermography which makes us question the many other medical applications that are available?

The simple principle for anatomical medical applications is the left side should always show equal results to the right side. This theory can be proven as shown in the following images. Can you see the thermal anomaly in each of the infrared scans shown in Figure 3?

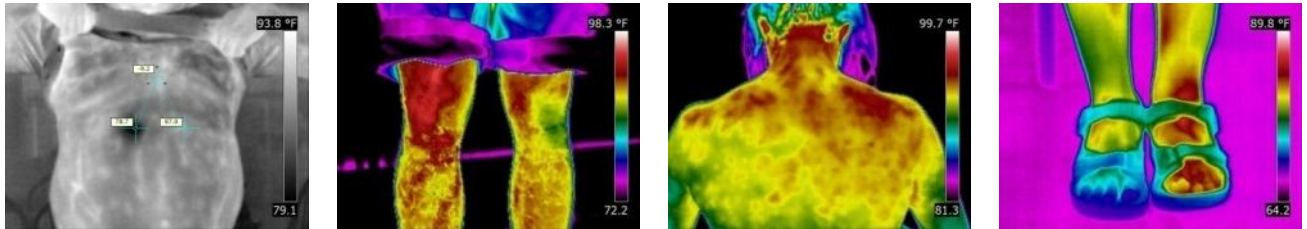


Figure 3. Find the thermal anomalies in each of the IR images in this figure.

The particular subjects of these cases each had a known condition they were able to verbally communicate. The problems are listed as follows from left to right: (1) Broken rib, (2) Leg injury, (3) Shoulder injury, (4) Foot surgery. Throughout the remainder of our paper, we will discuss and display images for several medical applications where verbal communication was not possible, therefore leaving the opportunity for infrared to do the talking.

CASE STUDIES

Figure 4 shows IR imagery of a zoo elephant showing definite asymmetry between the front legs which indicated soft tissue injury that was not identifiable on radiograph.

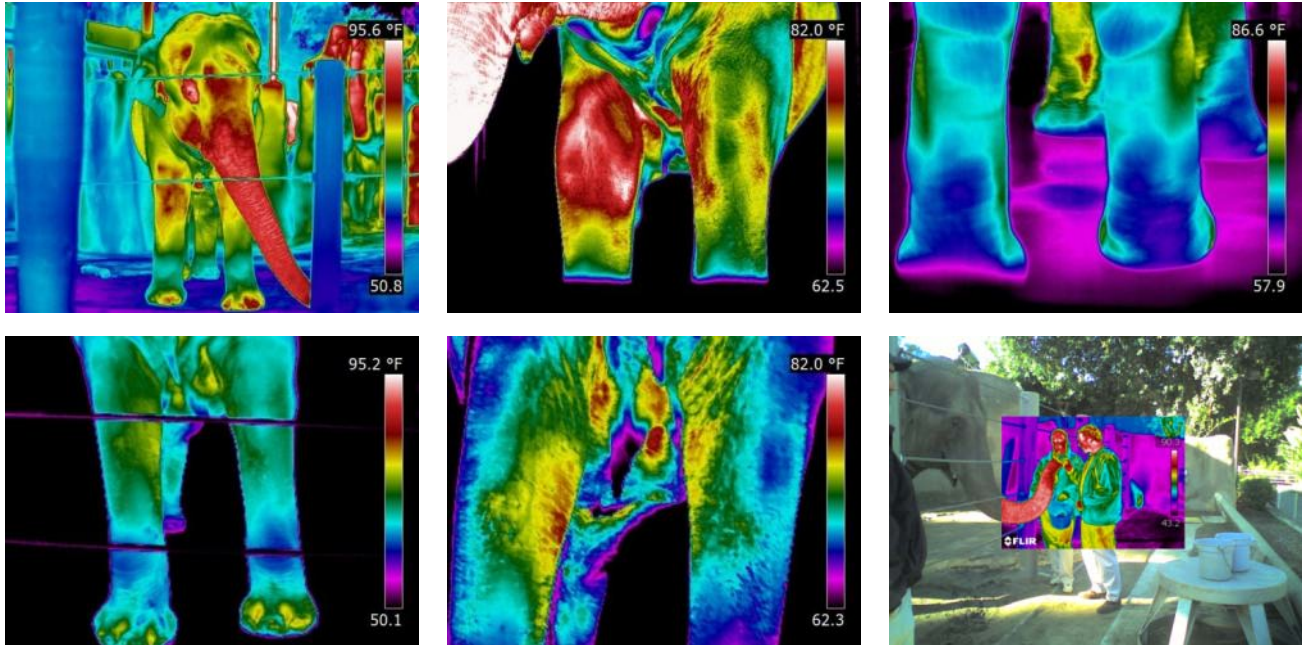


Figure 4. Zoo Elephant. November 24th, 2008 Imaging Session. Thermal Imaging service retained to map the blood flow for possible injury. As seen in IR images top left and top middle, there was definite asymmetry on the front legs. Top right shows rear view. Bottom left and middle IR images taken on a follow-up visit December 19th, 2008, show definite improvement. Slight heat indicating a tendon injury was still healing. Bottom right image is "elephant feeding fusion fun".

Figure 5 shows IR images of zoo giraffes. Giraffe on left has a known injury to left rear leg. IR imagery confirms lack of circulation in left rear leg indicated by arrows in Fig. 5.




Figure 5. Known injury in giraffe's left rear leg. The dark blue color in the leg and the lavender in the foot indicate a lack of circulation or nerve conduction.

Figure 6 shows IR images of a horse with a bulging disc. The IR imagery pick up the problem, later confirmed through radiographic imagery and analysis. A dorsal bulging disc can either move ventrally or laterally. A bulging disc that moves ventrally can cause paralysis due to pressure on the spinal cord.

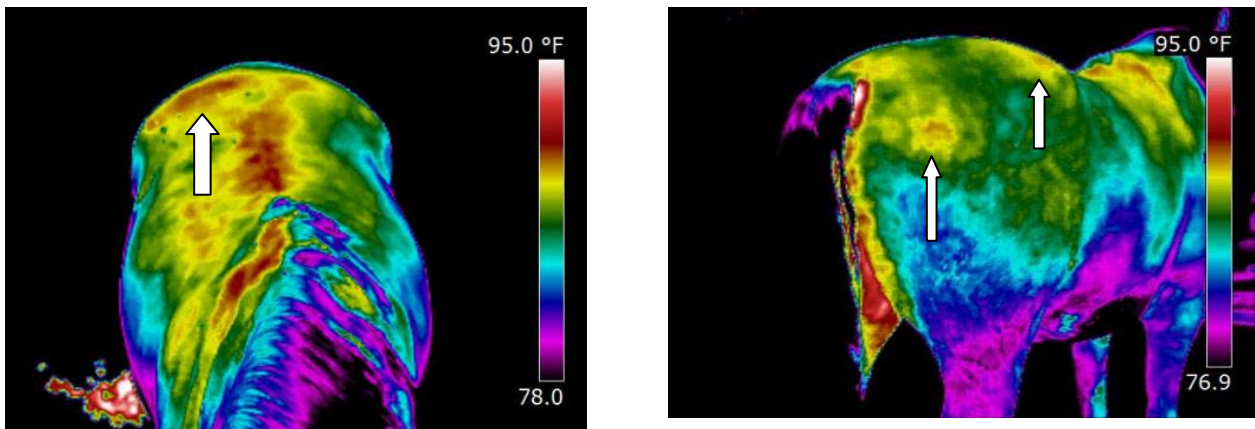


Figure 6. Client retained our services for a routine scan. Thermal image identified a hot spot which was later confirmed via radiograph to be a bulging disc. In this case you can see by the heat showing more on the right side as opposed to the left that this is a lateral, not ventral, condition.

Figure 7 gives more IR images of a horse, this time showing a different problem of thermal asymmetry in the neck and front feet. This can be an indicator of arthritis and/or nerve issues. The right hand IR image of the front legs shows abnormal heat patterns with cooler indicated by the arrow on the right fetlock and the circle indicating abnormal pattern on the right front fetlock.

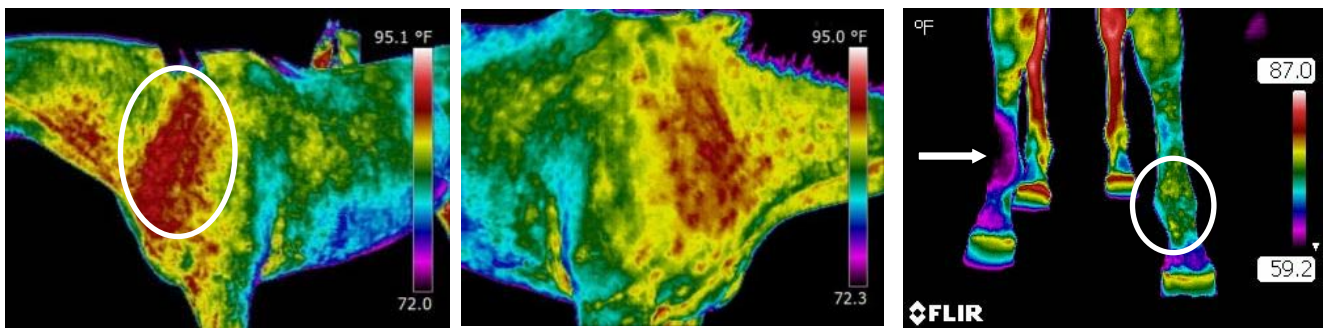


Figure 7. Asymmetry in the neck and front feet can be an indicator of arthritis and/or nerve issues, apparent in the far right IR image of the right front lower leg which reflects a cold area. You are also able to identify an issue in the image of the left forward fetlock by the abnormal heat pattern.

Figure 8 is another set of horse IR images this time showing abnormal heat over the coffin joint indicated by the arrow in the leftmost IR image. The center IR image shows the asymmetry compared to the left front foot. The right hand IR image shows (black arrows) higher heat in the sole of the right front foot.




Figure 8. IR image on left shows abnormal heat over the coffin joint (white arrow) of the right front foot. Center IR image clearly confirms there is more heat in the right front versus the left front foot (box). The final image once again offers an additional view in which you can confirm the increased heat in the sole of the right front (black arrows).

A veterinarian comments on IR thermography for aid in diagnosing problems with horses (Figures 9-13): "As a veterinarian, I often see EPM in horses. This condition can be very subtle in the early course of the disease. The IR image (Figure 9) is from a horse in the later stages of the disease. The diagnosis of EPM had been confirmed prior to the scan. However I am extremely impressed by the heat pattern image reflected down the spine (left IR image, Fig. 9). Thermography can be used not only as detection but also as a means of following the progress of the disease. This horse did not respond to conventional treatment and only had a slight response to the alternative therapy provided which eventually caused the horse the inability to stand and ultimately euthanized.

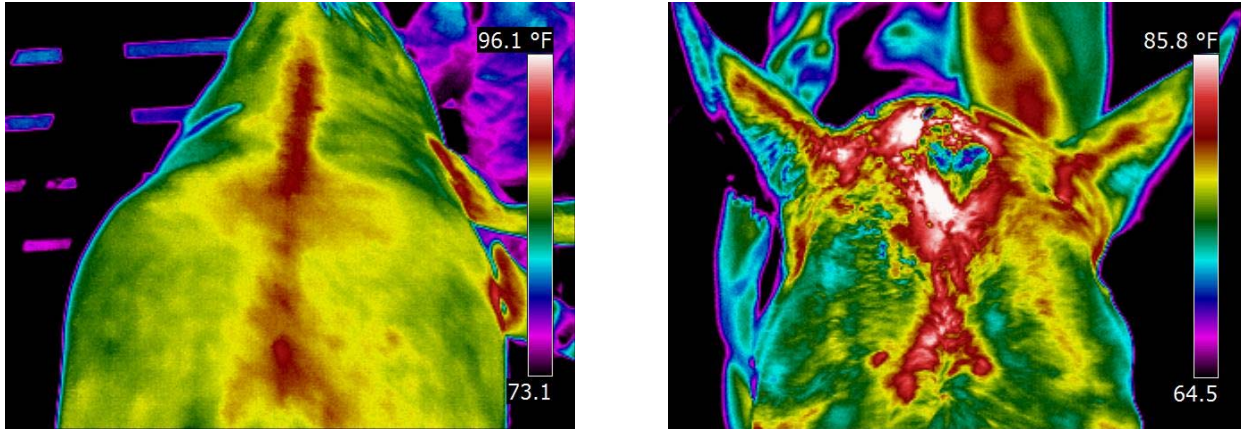


Figure 9. Left IR image of spinal area of horse with advanced EPM. Right IR image shows thermal pattern of horse with chronic draining abscess on the horses' poll.

The right hand IR image in Figure 9 is from a chronic draining abscess on the horse's poll. After taking the image, I realized this abscess was more extensive than it had appeared during observation and palpation. The sheet of muscle on the horses head had prevented me from feeling the extent of the abscess. After I incised the abscess, probed and flushed it, a drain tube could then be inserted for approximately 3 days allowing it to heal nicely.

Figure 10 shows a routine scan done on a race horse scheduled to leave for the track seven days after our appointment. The infrared scan identified an abnormal hot spot that was confirmed later as a fracture in the

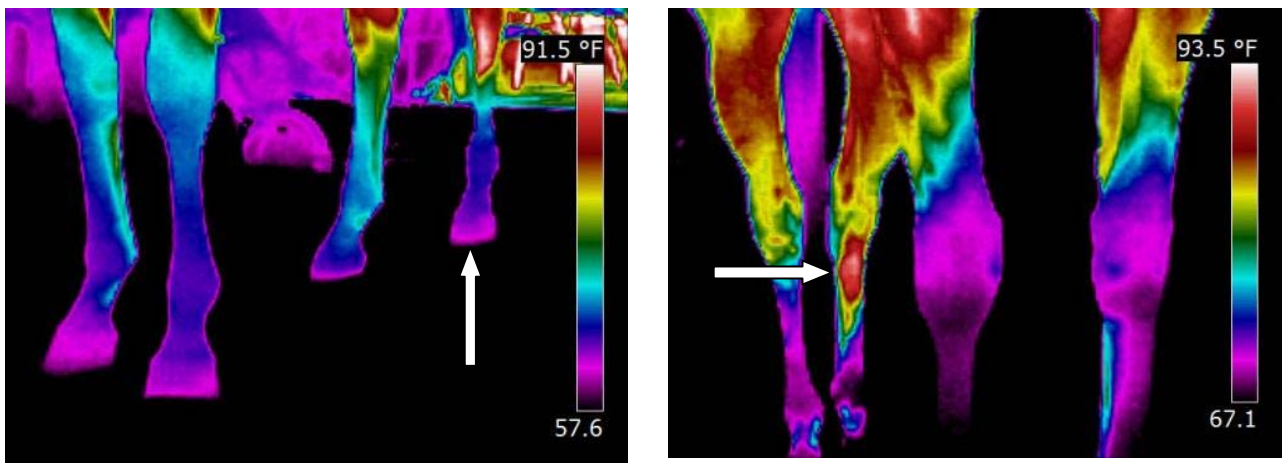


Figure 10. IR images indicate abnormal hot spot later confirmed later as a fracture in the cannon bone. Left IR image shows cooler left rear leg hoof temperature indicating shifting weight. Right IR image shows warmer leg temperature indicating injury.

cannon bone. Notice the rear leg hoof temperature being cooler, which in turn means the horse was shifting its weight due to the previously unknown injury. The horse was thankfully held back from track arrival which could have been a life saving decision for her.

Infrared on the horse in Figure 11 was done after an emergency evacuation took place during a barn fire. While the horse was being loaded into a trailer, it was suspected an injury may have taken place as the horse did not the act the same after the incident. The thermal scan showed asymmetry in the neck possibly indicating a lower cervical neck injury. It was later confirmed via a radiograph that a C6/7 fracture had in fact been present.

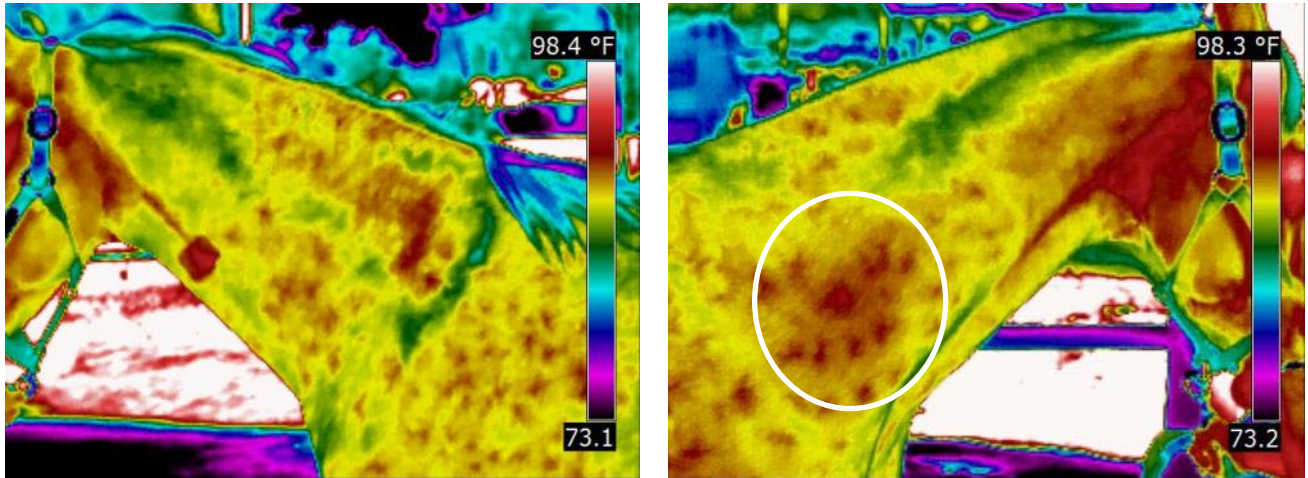


Figure 11. Comparing left and right IR images, the horse's neck showed thermal asymmetry possibly indicating a lower cervical neck injury. It was later confirmed via a radiograph that a C6/7 fracture had in fact been present.

The horse depicted in Figure 12 was a high-dollar jumper that had an ongoing problem. Each time while jumping the gate, it would veer to one side. The condition puzzled the owner, trainer and attending veterinarian as they were unable to identify any problems. It was later brought to their attention that an infrared scan might offer a clue. As identified in the thermograms in Figure 12, the two circled areas show abnormal back patterns. These patterns are consistent with a back problem called "kissing spines". The trainer confirmed a few weeks later the "kissing spines" diagnosis was accurate and had been confirmed via a radiograph.

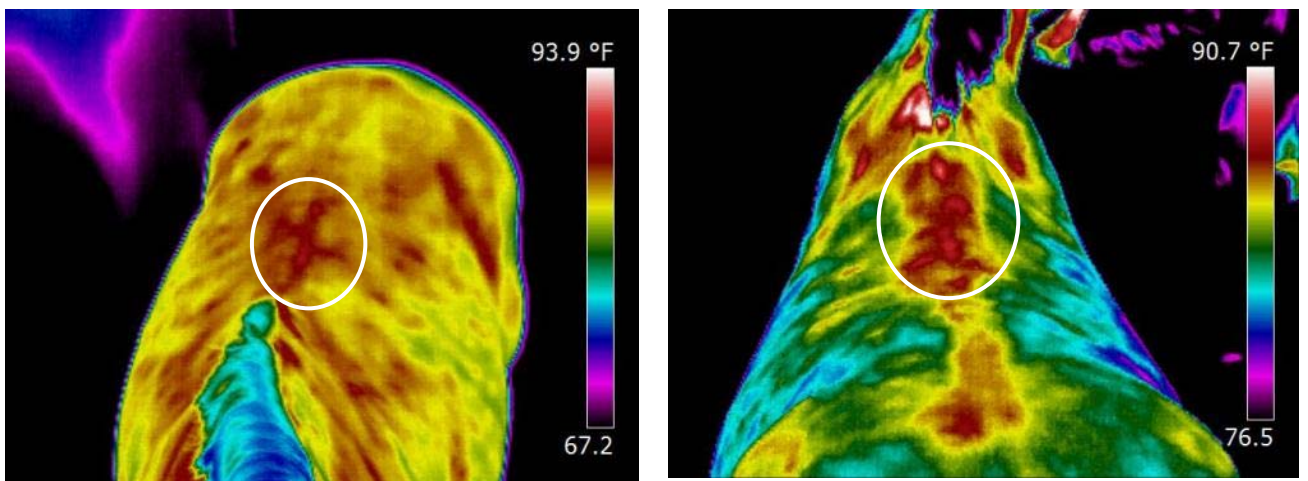


Figure 12. IR images of a horse's back show abnormalities indicated by circled areas. Suspected "kissing spines" confirmed by radiography.

The thermograms of the feet on the horse in Figure 13 showed increased heat at the toes. This could be due to inflammation such as acute laminitis or possibly could be due to excessive toe landing which could be produced by ataxia.

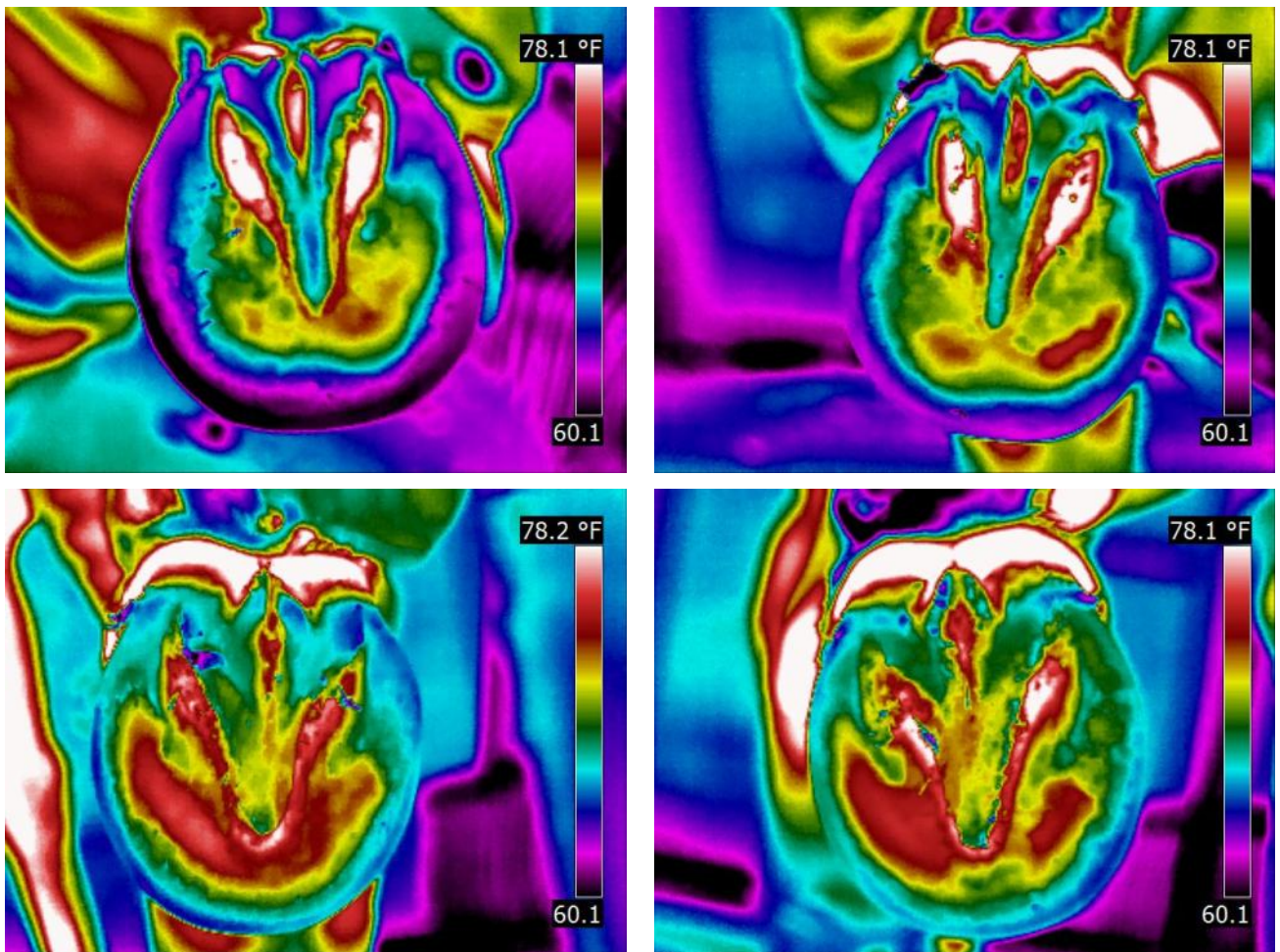


Figure 13. IR images show increased heat at the toes. This could be due to inflammation such as acute laminitis or possibly could be due to excessive toe landing which could be produced by ataxia.

TO EQUINE IR OR NOT

It is not uncommon for many to ask about the opportunities that exist with Equine Imaging. According to "WikiAnswers.com" [2], there are an estimated 9.2 million horses in America. That would be 9.2 million opportunities. Just think horses are just one of the many prey species that mask their pain, in turn leaving an opportunity for Infrared. Considering the images presented in this paper, you can see the viable opportunity out there however it will obviously take exposure and awareness in order to create the business.

It is often questioned if you need to be a Veterinarian to perform these types of surveys. Consider this, is it your medical doctor who is taking your x-ray when you break a bone or is it most common to find it is an x-ray technician? The same applies to infrared. Properly trained, you can be the infrared technician taking the image for any medical application. Do consider, just as an x-ray technician who is not legally capable of interpreting their images unless they are licensed to do so, you as a Thermographer would have to follow the same type of criteria. By aligning yourself with a trained veterinarian who specializes in thermography, you can offer your client the complete package. There are many interpretation services available to you from some doctors as well as veterinarians and you may even already have a relationship with both or either that just needs to be contacted or you can visit and online interpretation service at www.interpretIR.com.

OK, HOW MUCH CAN I MAKE AND IS THERE A BUSINESS OPPORTUNITY?

There are many variables involved in making a business happen, you must consider all of them. We are able to enlighten you for practical purposes, Peter's side which he will share as a non-veterinarian as well as Dean's side to be shared from the Veterinary practice, both are, two very distinct and different applications.

Peter's business is primarily imaging as he is called to scan a complete horse and Dean's infrared within a veterinary practice might be used as a specific tool in one area to help in the diagnosis of an animal. For a veterinary practice, the veterinarian might have a standard evaluation charge which may or may not include the use of infrared. Think of yourself as the client, would you choose the vet who probably has all standard technologies available to them or possibly just a few? Obviously these are individual results and your decision will obviously vary from a number of other clients.

"PETER"

As a non-veterinarian, I knew I had to offer the full approach with not only an imaging service but the ability for interpretation as this is a relatively new technology. Although it has been available for many years, it is only in the last decade or so that we are seeing some real opportunities arise. In my particular business, I offer a very diverse spectrum of application opportunities. If you view a paper I wrote in 2007 called "From Houses to Horses" [3], you will get a good idea of my clients and how I expanded my business. When it comes to income opportunity, the real money in horses is when you have multiple clients (working a barn for instance). I have had several appointments where I have booked up to 9 appointments in a row on one given day resulting in a profit close to \$850.00 for approximately 2.5 hours of work. Although this doesn't happen all the time, it is important that you realize it is a definite opportunity. According to a 2008 marketing survey with close to 200 Thermographers responding, the funds received for the above 2.5 hour job reported this type of wage would yield more than the average Level 1 Thermographer would receive during the average 8 hour work day. Hour for hour, fully booked, I make about four times the income when I do equine scans. My biggest recommendation is to receive the proper training along with the motivation necessary to build a successful business.

"DEAN"

As a veterinarian I use the infrared camera in my daily practice to demonstrate to my clients the location of the heat and pain in the animal's body. This can be an explorative procedure or a means of displaying the problem area in order to help the client better understand the condition. From a business standpoint this adds value to the clients visit to my practice and in turn to my client average transaction.

SUMMARY

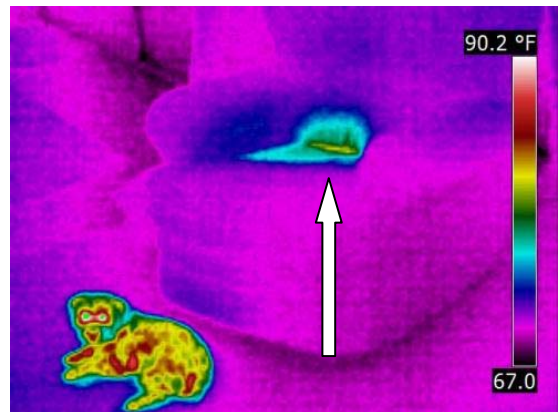
If you are considering adding infrared to your Veterinary practice or even learning to be an Equine Infrared Technician, do know that the right time to do so is right now. The infrared cameras have advanced in technology and as well have become affordable. The protocols, expectations and procedures have all advanced to a viable business opportunity. There are training organizations available that can help you easily transition into this opportunity and interpretation services that can piece it all together.

The rest is in your hands!

Well, just one more set of photos



Guilty looking isn't she?



Absolutely Guilty! Thank you Infrared for proving the case!

REFERENCES

1. M. A. Fauci, R. Breiter, W. Cabanski, W. Fick, R. Koch, J. Ziegler and S. D. Gunapala; *Infrared Physics & Technology; Volume 42; Issues 3-5; June 2001; Pages 337-344*
2. WikiAnswers.com: "How many horses in America"
3. Hopkins, Peter; "From Houses to Horses"; Proc. InfraMation; pp. 269-279; 2007

ACKNOWLEDGEMENTS

The authors wish to thank those that assisted in the creation of this paper including but not limited to the Infrared Training Center. ITC gave the inspiration to Peter Hopkins to add equine evaluations to his infrared business all because of a simple equine brochure hanging on the training center wall at the Billerica, MA facility. We would like to thank Dr. Tracy Turner-DVM and Dr. Jim Waldsmith-DVM for their support of the Equine Thermography field and specifically to Dr. Turner for his evaluations of many of the images presented in this paper. An additional thank you to equine thermographer-Shan de Wey for her extensive knowledge and ongoing enthusiasm in the Equine Thermography field.

ABOUT THE AUTHORS

Peter Hopkins has operated a successful home inspection company since 1996 (www.inspecdoc.com) which subsequently expanded into infrared in 2005 with the opening of SoCal Infrared (www.socalinfrared.com). Peter has found success in many areas of diversification including Equine Infrared. Peter was formally trained in Equine Thermography and today has advanced the procedure further to a well accepted and strong running business in itself. Peter has been quoted as being one of the most advanced non-veterinarian equine thermographers in the United States today by Dr. Tracy Turner-DVM, an equine thermography pioneer. Peter has been featured in a horse magazine editorial as well as interviewed on CBS News regarding the practice of equine infrared imaging. Peter in addition is licensed with the California Horse Racing Board as an Assistant to Veterinarian.

Peter is the co-founder of United Infrared (www.UnitedInfrared.com), a national network of contract thermographers which includes application-specific training and business coaching in a multitude of applications related to infrared technology including www.EquineIR.com. Peter Hopkins lives in Southern California with his wife Anna and their two children.

Peter Hopkins

Email: peter@unitedinfrared.com

Web: www.unitedinfrared.com

Phone: 888-SCAN-4-IR or 888-722-6447

Dean R. Bader- DVM graduated in 1966 from Kansas State University where he received his B.S. and in 1968 he received his DVM degree. Dean started a private practice in Palmer, Nebraska, and founded the Palmer Veterinary Clinic. In 1975, he moved to Torrance, California and purchased the Torrance Animal Hospital. He owned and operated the hospital from 1976 to 1983. In 1986 Dr. Bader moved to Placerville, California and in 1988 he opened the Shingle Spring Veterinary Hospital as the owner and operator and you can still find him there today. Through his ongoing commitment to animal health, Dean expanded his business to include infrared which he has found to be a great success. The advancement of this technology has led to his further commitment with the opening of the Equine Thermal Imaging Institute www.equinethermalimaginginstitute.com. The goal of this organization is to help train others interested in expanding into this opportunity with a proper foundation. Dean has not only been the veterinarian for the El Dorado County Fair for the past 18 years he has actively for the last 10 years, pursued an additional interest in alternative medicine which includes training in acupuncture from Colorado State University as well as Chiropractic and Electronic Medicine through the Electronic Medical Association, all of which his infrared technology has been very helpful in.

Dean R. Bader

Email: dean@deanbaderdvm.com

Web: www.equinethermalimaginginstitute.com

Phone: 530-677-0390